



Use of *N*-Butyl Cyanoacrylate With Metacryloxisulfolane (Glubran 2) Surgical Glue for Flapless Closure of Oroantral Communication

Nikola Burić, DMD, MSD, PhD*

Oroantral communication (OAC) is an abnormal connection between the maxillary sinus and the oral cavity, and it is mostly formed after the extraction of the first and second upper molar. The incidence of the formation of OAC is one in 180 extractions of the upper first molar and 1 OAC in 280 extractions of the upper second molar.¹ For many decades, the “gold standard” for the surgical repair of OACs of a diameter greater than 4 mm and alveolar depth less than 5 mm has been though the use of a buccal mucoperiosteal advancement flap, according to Rehrmann,² with 93% success.³

An OAC with the diameter of 3 to 4 mm and the alveolar depth greater than 5 mm, without permanent sinus pathology or foreign bodies, could be closed with alloplastic or biological material, ensuring stable blood and thus closing the OAC.

Cyanoacrylate glue was first synthesized in 1949 by Ardis and was first used in surgery in 1959 by Coover et al.⁴ During the Vietnam War in the 1960s, cyanoacrylate glue was used on wounded American soldiers, as an

Aim: To present first experience of the use *N*-butyl cyanoacrylate with metacryloxisulfolane (Glubran 2) synthetic surgical glue, in the non-surgical closure of oroantral communication (OAC).

Material and methods: Two OACs, created after the exodontia of tooth 27 in 2 female patients, were sealed and closed with Glubran 2 surgical glue and monitored OACs, until the epithelization of the sockets was ended successfully. Two months postclosure of OACs, the sealed OACs were evaluated on the panoramic image and Water’s view radiography.

Results: The extraction wounds with OACs were monitored until 23rd and 25th postinterventional days, when epithelization of socket ended successfully. On the panoramic image and Water’s view radiography, there were no radiological signs of maxillary sinus pathoses.

Conclusion: Glubran 2 can be successfully applied in the closure of OAC from 3 to 5 mm in diameter. (*Implant Dent* 2013;22:238–243)

Key Words: maxillary sinus, oroantral communication, cyanoacrylate glue, Glubran 2

emergency tool to stop the bleeding on the battlefield. The structural ability to enhance the coagulation process and to create a mechanical barrier at the site of breakdown of tissue enabled glues, adhesives, and sealants to be used successfully in clinical practice in the subsequent years. Medical reports on the use of cyanoacrylates as tenacious adhesives have also shown their successful use in the closure of abdominal fistulas⁵ and gastrointestinal fistulas.⁶

Based on this premise, rather than on the constant clinical demands for a minimum invasive procedure in surgery, the closure of OAC with surgical glues or sealants would be a worthwhile biological and clinical goal. Thus, interest has emerged, in a simplified, time-saving, and reliable technique in the

closure of OAC with synthetic surgical glue, which has adhesive and haemostatic actions on the tissue, when applied.

Glubran 2 (GEM S.r.l., Viareggio, Italy) is a new synthetic tissue adhesive (in Europe), which is a result of the mixture of 2 monomers: *N*-butyl-2-cyanoacrylate and metacryloxisulfolane, produced in a “ready to use” cartridge-applicator. It is manufactured for internal use, and in a moist environment (blood or water) and in contact with living tissue, Glubran 2 polymerizes rapidly to create a thin and elastic film of high tensile resistance, thus enabling firm adherence of tissues. It also has better properties than the previously available cyanoacrylate adhesives, in terms of elasticity and polymerization temperature, which occurs at 45°C,

*Head of Oral Surgery, Assistant Director of Clinic of Stomatology, Medical School, Stomatology, University of Niš, Niš, Serbia.

Reprint requests and correspondence to: Nikola Burić, DMD, MSD, PhD, Clinic of Stomatology, Oral and Maxillofacial Surgery, Dr Zorana Djindjica 52 Boulevard, 18000 Niš, Serbia, Phone: +381184538655, Fax: +381184537919, E-mail: nburić@yahoo.com

avoiding thermal damage to the surface and underlying tissues.⁷

To date, there has only been 1 report⁸ on the use of cyanoacrylate surgical glue (Glubran 2) in a surgical procedure, combined with the buccal advancement flap in the closure of the oroantral fistula.

We present our first experience of the use of Glubran 2 synthetic surgical glue, manufactured for internal use, in the nonsurgical closure of OACs, which occurred after the exodontia of the upper molar tooth, and provide an explanation of the procedure.

CASE REPORTS

Before the intervention, patients were provided with the description of the procedures and possible complications. Patients were treated in accordance with the ethical principles of the Helsinki's Declaration and the ethical principles of treating patients at our clinic. They were interviewed and informed of the risks of the proposed procedure, and they gave consent to the procedure. Medical history data were taken to rule out the existence of a previous maxillary sinus disease or another paranasal sinusitis.

A standard panoramic image was taken before and 2 months after closure of OAC, with the radiographic apparatus ORTHOPOS XG^{Plus} (SIRONA, Blenheim, Germany) with kilovolt in the range between 65 and 80 kV and 16 mA. In addition, Water's view radiograph was used before the intervention and 2 months postclosure of OAC. Metal probes with a diameter from 3 to 5 mm were used for the measurement of the maximum diameter of the OAC.

The following procedures⁹ were performed before the sealing of OAC with Glubran 2: (1) inspection of the extraction wound with subsequent irrigation with a sterile physiological solution to eliminate any residue in the form of a foreign body; (2) irrigation of the maxillary sinus through the OAC with 15 to 20 mL of a sterile physiological solution, antibiotics (Clindamycin-MIP, 600 mg/2 mL solution; St. Ingbert, Germany), and corticosteroids (dexamethasone, 1 mL of the 4-mg/mL solution; Galenika a.d., Belgrade), with the patency of the sinus ostium of the

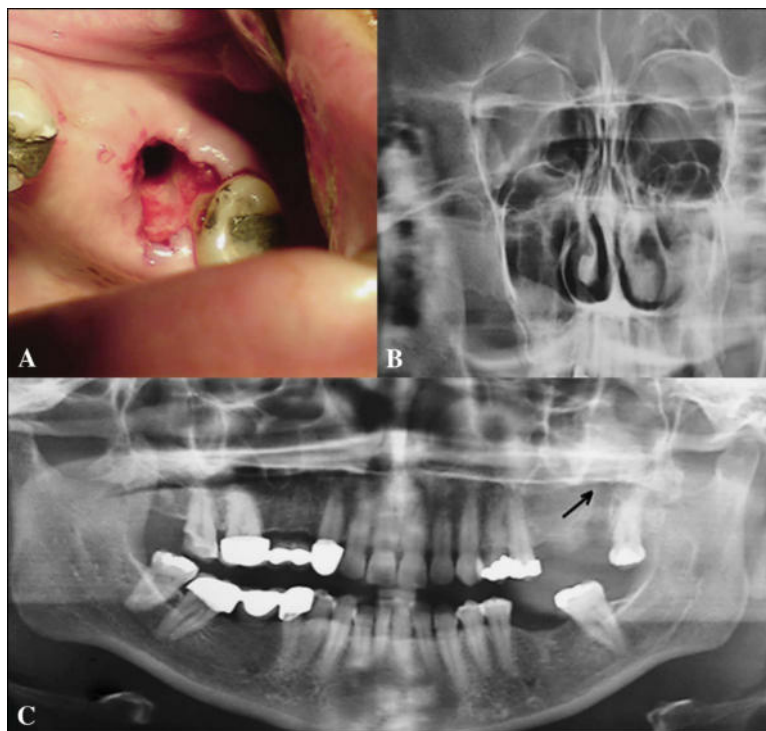


Fig. 1. **A**, Intraoral appearance of OAC at the site of the extracted tooth 27; **B**, the coronal view shows pathosis of the right maxillary sinus and the presence of mucocoele in the left maxillary sinus; **C**, panoramic radiography shows the extent of OAC (arrow).

maxillary sinus recorded on the ipsilateral nostril; (3) curettage processing of the extraction wound to provoke alveolar bleeding; (4) sealing the OAC with Glubran 2 surgical glue “drop-by-drop” from the syringe of 1 mL, with extreme caution for the purpose of avoiding leakage of the surgical glue into the oral cavity and the surrounding oral mucosa, with constant vacuum aspiration; (5) application of a sterile swab over the sealed OAC after the cessation of polymerization time for Glubran 2 surgical glue (60–90 seconds), with the patient holding the sterile swab in place over the next 15 to 20 minutes by biting; (6) the patient was instructed to take nasal

decongestant and antibiotic therapy with clindamycin (Clindamycin-MIP; St. Ingbert, Germany; 600 mg every 12 hours for at least 7 days) and until the end of the therapy; and (7) to avoid provoking OAC failure by blowing the patient's nose, not to rinse the oral cavity or endanger the closed OAC mechanically by tooth brush, and to adhere to a soft diet 24 hours after the procedure. The healing of extraction wounds was clinically inspected until the cessation of epithelization of the alveolus, which was recorded.

Case 1

An X-year-old white woman with an OAC formed in the left maxilla was

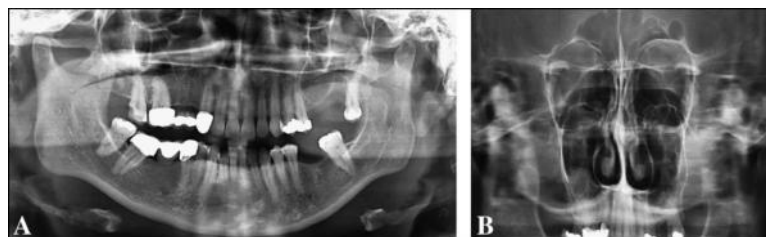

Fig. 2. **A**, Panoramic radiography shows the absence of pathoses at the site of the previously glued OAC; **B**, the coronal view of the left maxillary sinus shows the absence of any pathoses, whereas significant pathoses are still present in the right untreated maxillary sinus.

referred to our department. A history of complaints revealed that the patient had had an exodontic treatment of the maxillary left second molar with a large caries lesion, necrotic pulp, and periapical radiolucency the day before. The general health status of the patient and blood and urine analyses were not contributory. The extraoral examination revealed no pathology, whereas an OAC was present in the region of the second left molar, after an intraoral examination (Fig. 1, a). Before the intervention, the panoramic image and Water's view radiograph showed the presence of the OAC and a slight opacification of the maxillary sinus (Fig. 1, b and c) in the form of a mucocele of the left maxillary sinus, suctioned by syringe through the OAC before closure with Glubran 2. Metal probes in the diameter of 5 mm were used for the measurement of the maximum diameter of the OAC. The OAC was sealed and closed with Glubran 2 in the described manner. After the postclosure day 7, the patient was regularly examined 2 times per week for removing the excess particles of Glubran 2, which remained in the form of flakes on the socket wall. The OAC was completely closed on the 23rd postinterventional day. Two months postclosure of OAC, the sealed OAC was evaluated on the panoramic image and Water's view radiography to ascertain whether the performed procedure justified the expected successful result (Fig. 2, a and b).

Case 2

A 44-year-old woman with an OAC in the left maxilla, previously treated in another dental institution, was referred to our department. The OAC formed within 48 hours before admission to our institution. The patient's medical and family history was unremarkable. On clinical examination, there was an OAC as a consequence of the exodontia of the second left upper molar (Fig. 3, a). Metal probes in the diameter of 3 mm were used for the measurement of the maximum diameter of the OAC. The patient was routinely diagnosed with the use of the panoramic x-ray imaging technique and Water's view radiograph, which showed the absence of maxillary sinus disease and the breakdown of bone septa in the

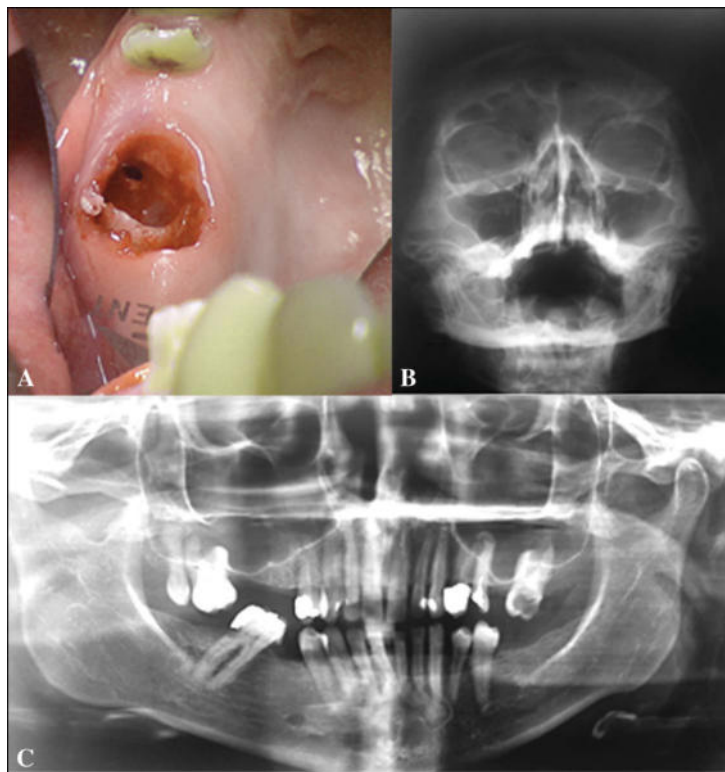


Fig. 3. **A**, Intraoral appearance of OAC (mirror images) at the site of the extracted tooth 27; **B**, Water's view radiography shows discreet left pathoses of the left maxillary sinus; **C**, panoramic radiography shows a nonvital second upper molar tooth before the exodontia.

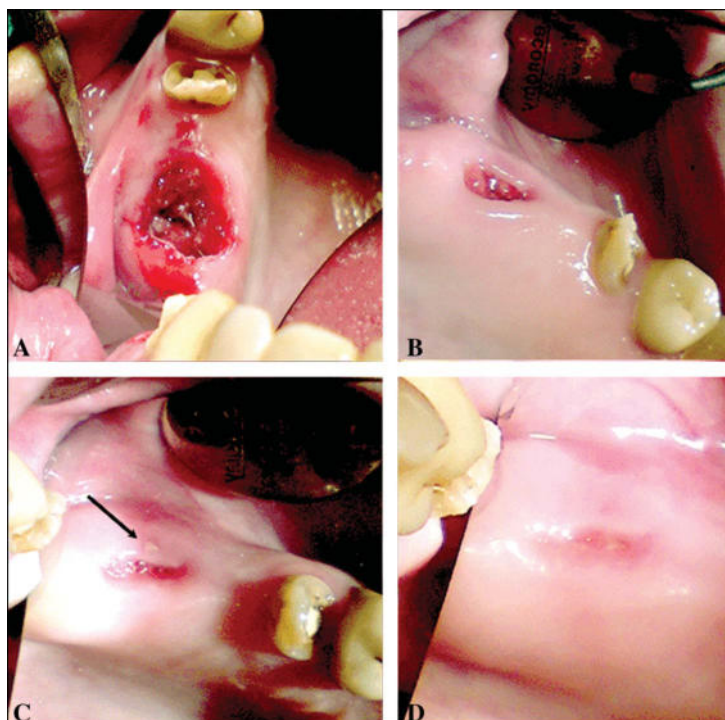


Fig. 4. **A**, Intraoral appearance of the OAC sealed with Glubran 2; **B**, shrinkage of the alveolar socket after 7 days; **C**, almost normal healing of the extraction socket with the surface presence of Glubran 2 flakes (black arrow); **D**, successful epithelization of the extraction wound with an OAC on the 25th postinterventional day (mirror images).

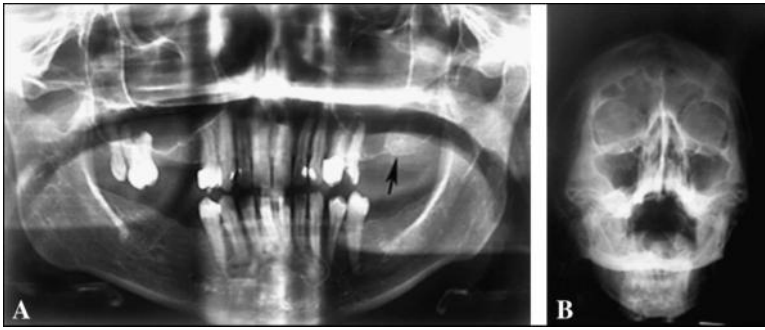


Fig. 5. **A**, Panoramic radiography shows dense bone opacification at the site of the extracted tooth 27 (arrow); **B**, Water's view radiography shows the absence of maxillary sinus pathoses.

alveolus of the second left upper molar (Fig. 3, b and c). According to the described protocol, the OAC was sealed with Glubran 2 (Fig. 4, a). At the end of epithelization, a few excess particles of Glubran 2, which remained in the form of flakes, emerged in the mucosa over the socket with the OAC. On 25th post-interventional day, the OAC was completely closed (Fig. 4, d). Two months postclosure of OAC, radiography was performed to examine the postclosure morbidity of the treated tissue. There were no radiological signs of inflammatory disease of the maxillary sinus or the alveolus and OAC treated with Glubran 2 (Fig. 5, a and b).

DISCUSSION

To the best of the author's knowledge, these are the first cases of a successful closure of OAC with the single use of Glubran 2 surgical glue. There are numerous reports concerning the successful use of alloplast in the closure of OAC. The latest reports⁹ showed promising results by using polyglycolic acid/poly-L-lactic acid (90/10) (Ethisorb) in the nonsurgical closure of OAC. Considering the surgical history of OAC, there is a myriad of other successful reports of the use of alloplasts in the closure of OAC. Al-Sibah and Al-Badri¹⁰ described their experience with soft polymethylmethacrylate in the closure of the oroantral fistula. Goldman et al¹¹ used gold foil in the closure of OAC, whereas Mitchell and Lamb¹² described the immediate closure of OAC with a collagen implant. Other authors have described the use of fibrin glue in the closure of OAC,¹³ collagen-

type I membrane for OAC closure located on the lateral sinus wall,¹⁴ and the sandwich technique and guided tissue regeneration in the closure of OAC.¹⁵ The specific chemical structure of cyanoacrylates as synthetic compounds, and used as surgical glues, enables them to firmly bond living tissue through the process of rapid polymerization in contact with water or blood.¹⁶ However, cyanoacrylate glue was not FDA-approved for medical use, mainly because of the side effects such as skin irritation and the generation of heat above normal body temperature. Cyanoacrylate glue, Histoacryl (B Braun, Melsungen, Germany), has been used extensively in the endoscopic procedure for the last 20 years.^{17,18} In 1998, the FDA approved 2-octylcyanoacrylate (Dermabond; Ethicon, Inc., Somerville, NJ) for external application, and some authors have reported favorable clinical experiences regarding the sutureless closure of very thin skin, such as eyelid skin wounds.¹⁹

Another surgical synthetic glue, ie, *N*-butyl-2-cyanoacrylate with metacryloxisulfolane (Glubran 2; GEM S.r.l.), has recently been approved for internal-endoscopic use in Europe. Cyanoacrylate glue has recently been used by various specialists, such as orthopedic surgeons,²⁰ ophthalmologists,²¹ neurosurgeons,²² and urologists.²³ Glubran 2 Surgical Glue is a class III medical-surgical product (for internal and external surgical use), which completely fulfills the requirements of the European Directive on Medical Devices 93/42/EEC.

Even though the conventional surgical closure of OAC with the buccal advancement mucoperiosteal flap is an

simple and efficient technique, it has postoperative surgical morbidity, and the most frequent are pain, swelling, discomfort because of suture swelling, reduces the depth of the buccal vestibular sulcus, and possible hemorrhage from the incised periosteum. The minimal invasive procedure in surgery is more beneficial for the patients if it provides the same or better results than surgery. This was possible in the described cases with Glubran 2. The application of cyanoacrylate glue in the closure of OACs is a painless, rapid, and easy technique, as there is no need for suture removal.

This article also describes an exceptional haemostatic and adhesive result in the closure of OACs. This is not a surprise because Glubran 2 has these properties, with the subsequent production of an effective antiseptic barrier against germ colonization, commonly found in the oral cavity. Although it is packed in a special vial, we found that it was not suitable for the closure of OAC as the vial may easily leak glue from the alveolus into the surrounding tissue of the oral cavity. Hence, it is imperative to use a syringe and aspirate the glue from the vial and then apply the glue drop by drop, slowly closing the OAC, with the constant aspiration of the leaking glue. The use of Glubran 2 in the closure of OAC would probably be more practical if it were used in combination with a collagen material, to prevent the leakage of glue out of the alveolar socket, but this method has not been the subject of this work.

However, there are two questions about Glubran 2 used in this article, which remain unanswered and raise doubts. One is the biological fate of Glubran 2 on the internal tissue. The possible toxic reaction of the highly sensitive internal tissue, ie, sinus mucosa, remains a concern. To date, experimental data has shown that Glubran 2 is less harmful, when used for the embolization of the a-v fistula on the carotid common artery and the jugular vein in sheep, because of the lower thermal effect, compared with Histoacryl glue.²⁴ Safe aerostatic effects on the resected pulmonary parenchyma were presented in an experimental study on a pig's resected pulmonary

tissue. No differences were noted between air loss and the survival of experimental pigs considering the conventional technique and Glubran 2. The authors concluded that aerostatic effects of Glubran 2 on pulmonary tissue are biologically beneficial and the same as in the case of mechanical postresection suturing techniques.²⁵

The second concern is the influence of Glubran 2 on bone tissue, ie, the alveolar socket. Clinical results concerning the use of Glubran 2 to seal the oroantral fistula (adjunctable material) in combination with the mucoperiosteal buccal flap and absorbable sutures proved successful. In the postoperative follow-up period from 6 months to 3 years, authors did not observe any reaction or medical problems in relation to the applied treatment.⁸ Other authors have used Glubran 2 for the fixation of bone pieces used for the repair of the anterior cranial fossa bone defects in a 12-year-old boy with brain injury, and the subsequent formation of brain abscess caused by *Streptococcus pyogenes*. No complications were observed in the postoperative course in relation to the use of Glubran 2 on the bone tissue in the proximity of severe infections.²⁶ Experimental results on mongrel dogs with artificial, surgically created, standardized dehiscence bone defects on the buccal side of the installed implants showed that cyanoacrylate-combined calcium phosphate can serve as scaffold and substitute for the barrier membrane during a guided bone regeneration procedure.²⁷ As a possible inert material, Glubran 2 may be present for years to come. Therefore, more investigation is essential, because this material may inhibit the formation of bone regeneration in the alveolar socket.

It has been observed that Glubran 2 needs a longer time period to be removed from the mucosa over the alveolar socket. The complete epithelization of the extraction wound in both patients described in this article lasted until the 23rd and 25th day, respectively, with the elimination of flakes of Glubran 2 residues. This observation led to the opinion that, in an open environment (oral cavity) and from a biological standpoint, Glubran 2 requires a longer time period to be eliminated from the site of

application. Other reports dealing with the use of cyanoacrylate glue in periodontal procedures for the fixation and prevention of shrinkage of free gingival graft showed better results compared with the control group, where the graft was sutured to the recipient bed by 5-0 silk sutures.²⁸ In the modified Widman flap surgery, Nectacryl (*N*-butyl 2-cyanoacrylate) serves as a more efficient tool for the sutureless closure of the flap than the conventional suture technique with 3-0 silk sutures.²⁹ However, because of the short-term follow-up, the full biological behavior of Glubran 2 could not be definitely concluded because this material may inhibit formation of bone in the socket.

CONCLUSIONS

The described technique with surgical glue in closure of OACs was an easy, an efficient, and a safe alternative to surgical closure of OACs. The use of Glubran 2 in the nonsurgical closure of OAC was successful in the permanent obturation of OACs. Moreover, Glubran 2 showed the rapidity of the polymerization process and permanent alveolar hemostasis in its application during the closure of OACs ranging from 3 to 5 mm. A complete epithelization of alveolar sockets, and thus, closure of OACs occurred on the 23rd and 25th postclosure day, respectively. However, further studies with longer clinical and radiological follow-ups (6 and 12 months postclosure) would help to better show the place that Glubran 2 cyanoacrylate surgical glue occupies in the treatment of OAC.

DISCLOSURE

The author claims to have no financial interest, either directly or indirectly, in the products or information listed in the article. The author also claims that there were no sources of funding for this study.

REFERENCES

1. Ehrl PA. Oroantral communications. Epicritical study on 175 patients, with special concern to secondary operative closure. *Int J Oral Surg*. 1980;9:351-358.
2. Rehrmann A. Eine methode zur Schliessung von Kieferöhlenperforationen.

Dtsch Zahnartzl Wschr. 1936;39:1136-1139.

3. Killey HC, Kay LW. An analysis of 250 cases of oro-antral fistula treated by the buccal flap operation. *Oral Surg Oral Med Oral Pathol*. 1967;24:726-739.

4. Coover HW, Jr, Joyner FB, Shearer NH Jr, et al. Chemistry and performance of cyanoacrylate adhesives. *Soc Plast Eng J*. 1959;5:413-417.

5. Seewald S, Groth S, Sriram PV, et al. Endoscopic treatment of biliary leakage with n-butyl-2 cyanoacrylate. *Gastrointest Endosc*. 2002;56:916-919.

6. Lee YC, Na HG, Suh JH, et al. Three cases of fistulae arising from gastrointestinal tract treated with endoscopic injection of histoacryl. *Endoscopy*. 2001;33:184-186.

7. Leonardi M, Barbara C, Simonetti L, et al. Glubran 2: A new acrylic glue for neuro-radiological endovascular use experimental study on animals. *Interv Neuroradiol*. 2002;8:245-250.

8. Hajioannou J, Koudounarakis E, Alexopoulos K, et al. Maxillary sinusitis of dental origin due to oroantral fistula treated by endoscopic sinus surgery and primary fistula closure. *J Laryngol Otol*. 2010;124:986-989.

9. Buric N, Jovanovic G, Krasic D, et al. The use of absorbable polyglactin/polydioxanone implant (Ethisorb®) in non-surgical closure of oro-antral communication. *J Cranio-Maxillofac Surg*. 2012;40:71-77.

10. Al-Sibah A, Al-Badri A. The use of soft polymethylmethacrylate in closure of oroantral fistula. *J Oral Maxillofac Surg*. 1982;40:165-166.

11. Goldman EH, Stratigos GT, Arthur AL. Treatment of oroantral fistula by gold foil closure: Report of a case. *J Oral Surg*. 1969;27:875-877.

12. Mitchell R, Lamb J. Immediate closure of oroantral fistula with collagen implants. A preliminary report. *Br Dent J*. 1983;154:171-173.

13. Gattinger B. Der verschluß von mund-antrum-verbindungen mit dem lyophilisierten fibrinklebesystem. *Zahnartzl Prax*. 1984;35:8-10.

14. Becker J, Neukam FW, Schliephake H. Restoration of lateral sinus wall using a collagen type I membrane for guided tissue regeneration. *Int J Oral Maxillofac Surg*. 1992;21:243-246.

15. Ogunsalu C. A new surgical management for oro-antral communication: The resorbable guided tissue regeneration membrane—Bone substitute sandwich technique. *West Indian Med J*. 2005;54:261-263.

16. Seewald S, Sriram PVJ, Nagra M, et al. The expert approach: Cyanoacrylate glue in gastric variceal bleeding. *Endoscopy*. 2002;35:926-932.

17. Quinn J, Wells G, Sutcliffe T, et al. A randomized trial comparing octylcyanoacrylate tissue adhesive and sutures in the management of lacerations. *JAMA*. 1997;277:1527–1530.
18. Seewald S, Groth S, Sriram PV, et al. Endoscopic treatment of biliary leakage with n-butyl-2 cyanoacrylate. *Gastrointest Endosc*. 2002;56:916–919.
19. Burić N. The application of Dermabond® skin adhesive in the reconstruction of the eyelid injury. *Acta Stomatologica Naissi*. 2004;20:319–324.
20. Yilmaz C, Kuyurtar F. Fixation of a talar osteochondral fracture with cyanoacrylate glue. *Arthroscopy*. 2005;21:1009.e1–1009.e3.
21. Sharma A, Kaur R, Kumar S, et al. Fibrin glue versus N-butyl-2-cyanoacrylate in corneal perforations. *Ophthalmology*. 2003;110:291–298.
22. Wakhloo AK, Perlow A, Linfante I, et al. Transvenous n-butyl-cyanoacrylate infusion for complex dural carotid cavernous fistulas: technical considerations and clinical outcome. *Am J Neuroradiol*. 2005;26:1888–1897.
23. Aslan G, Men S, Gulcu A, et al. Percutaneous embolization of persistent urinary fistula after partial nephrectomy using N-butyl-2-cyanoacrylate. *Int J Urol*. 2005;12:838–841.
24. Leonardi M, Barbara C, Simonetti R, et al. Glubran 2: A new acrylic glue for neuroradiological endovascular use. Experimental study on animals. *Interv Neuroradiol*. 2002;8:245–250.
25. Davoli F, Sellitri F, Brandolini J, et al. Use of coagulant spray glue (Glubran 2) for aerostatic purposes in pulmonary parenchyma resections in pigs: A preliminary study. *Eur Surg Res*. 2009;43:360–364.
26. Gulsen S, Aydin G, Cömert S, et al. Rapid development of brain abscess caused by streptococcus pyogenes following penetrating skull injury via the ethmoidal sinus and lamina cribrosa. *J Korean Neurosurg Soc*. 2010;48:73–78.
27. Lee JS, Ko SH, Kim YT, et al. Guided bone regeneration using cyanoacrylate-combined calcium phosphate in a dehiscence defect: A histologic study in dogs. *J Oral Maxillofac Surg*. 2012;70:2070–2079.
28. Güncü GN, Keçeli HG, Ercan E, et al. Evaluation of sutureless free gingival grafts. *Clin Dent Res*. 2012;36:29–35.
29. Padhye A, Pol DG. Clinical evaluation of the efficacy of n-butyl 2-cyanoacrylate as a bioadhesive material in comparison to conventional silk sutures in modified Widman flap surgery in the anterior region. *J Indian Dent Assoc*. 2011;5:899–904.